

Case Study

Erosive vulvovaginal gingival lichen planus, a rare cause of dysuria and hematuria misdiagnosed as urinary tract infections

Nisreen Fuad Bajnaid

King Abdulaziz University, Jeddah, Saudi Arabia. E-mail- nisreenbajnaid@gmail.com.

Accepted 10 September, 2013

This is a case report of 30 years old female patient who presented with almost monthly episodes of urinary symptoms misdiagnosed and treated as recurrent urinary tract infections with poor response. On physical examination of this lady, features suggestive of lichen planus involving both the oral and genital area were found and immediately she was placed on systemic and local immunosuppressive therapy with excellent response for almost a year, but unfortunately she was lost for follow up.

Key words: Lichen planus, vaginitis, erosive vulvovaginal, gingival syndrome, immunosuppressive drugs.

INTRODUCTION

Lichen planus (LP) is an inflammatory dermatosis of the mucocutaneous surfaces that can present with a variety of clinical manifestation (Julia et al., 2009). The etiology is unknown but immune mediated mechanism involving activated T cells particularly CD8+ cells directed against basal keratinocytes was proposed.

The most common LP subtype involving the genital area is erosive LP, with hypertrophic or papulosquamous LP being less common variants. In women with LP of the genitalia, the vulva or vagina may be affected. Without adequate treatment, substantial erosion and anatomic disfigurement may occur (Julia et al., 2009).

In men with LP of the genitalia, the glands penis is most commonly involved (Julia et al., 2009). This case was reported for two reasons. First, the presentation was quite unusual. Secondly, emphasis was placed on the importance of thorough physical examination in all patients as it is the gate for successful diagnosis and proper management.

CASE REPORT

A 30 years old morbidly obese female, mother of two daughters, who is known to have mild intermittent bronchial asthma and non insulin dependent diabetes mellitus (NIDDM) on metformine, was admitted on 2nd of March 2010 under care of urology service as a case of recurrent UTI and acute pyelonephritis that failed to respond to antibiotics administered in a private hospital.

She was referred to the infectious disease service for further evaluation and proper antimicrobial selection. Her main complains were dysuria, frequency, and suprapubic pain, gross hematuria sometimes associated with clots, subjective fever and bilateral flank pain.

The problem started 8 months prior to her presentation after she gave birth to her second daughter. During the 3rd trimester of that pregnancy, she developed acute vaginal bleeding after receiving a course of steroid for allergic skin rash.

She was admitted under Obstetric and Gynaecology, and underwent surgical exploration. Vaginal rings were found and released. During the procedure, vaginal biopsy was taken and histopathology showed only inflammatory cells. Since that time she was suffering from repeated attacks of dysuria, frequency, and hematuria that were diagnosed as "UTI" with a frequency of 1 attack per month. On further questioning, she gave history of vaginal pain and irritation with smelly discharges and severe dyspareunia since her marriage 11 years ago.

Investigations for possibility of congenital anomalies of GU system as a cause of her symptoms were all negative, though the renal stones and uterine prolapse were excluded. She has skin allergy in the form of urticarial rash and she was allergic to ranitidine, ceftriaxone and aspirin.

Past medical history is positive for PID twice, appendectomy, cholecystectomy and release of what is thought to be vaginal adhesions. On physical examination,

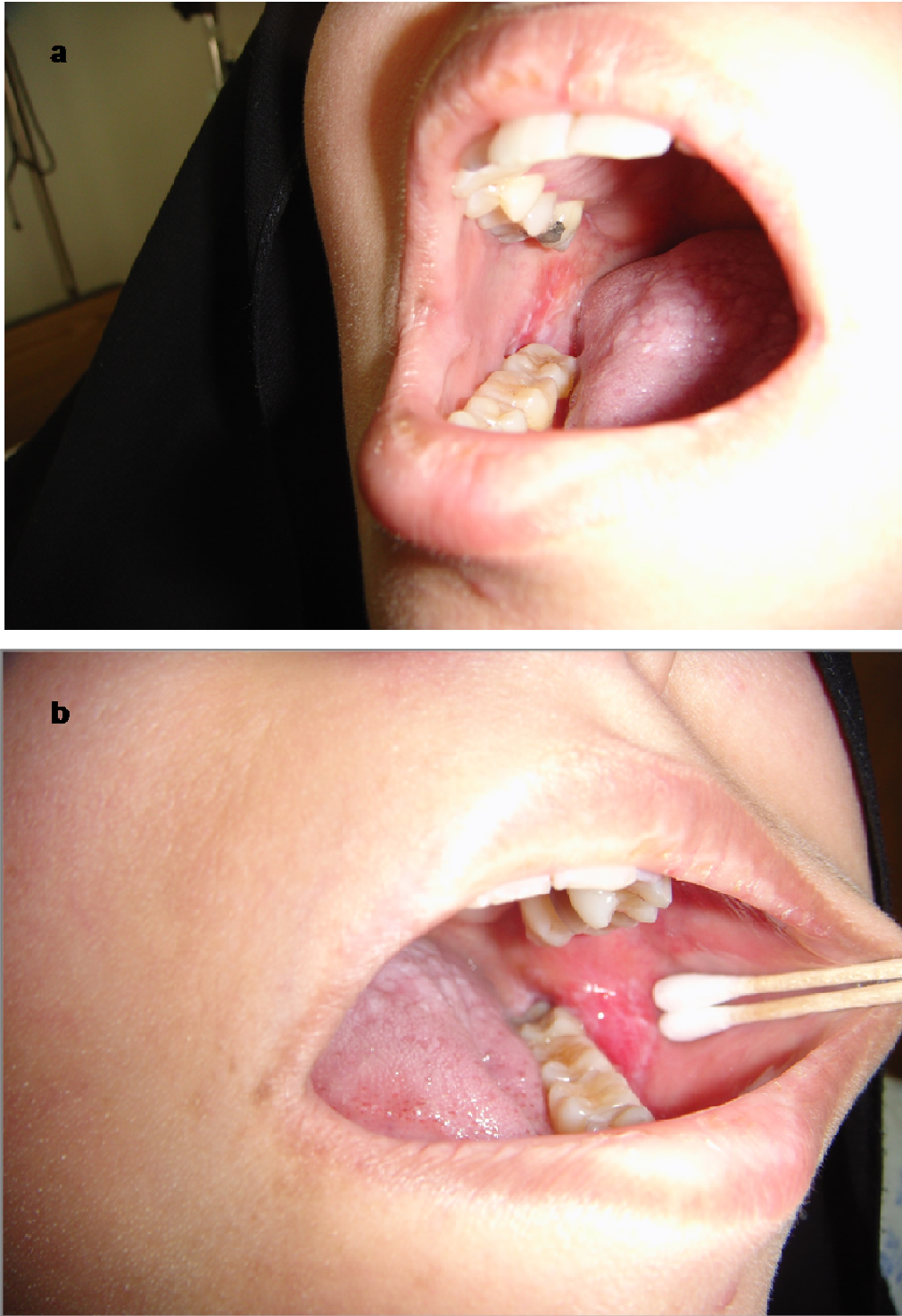

Figure 1. Lacelike plaques on buccal mucosa bilaterally.

it was observed that she was afebrile with BP 104/60, and was pale with no jaundice. Oral examination showed whitish lacelike plaques on the buccal mucosa opposite the lower molar teeth bilaterally (Figure 1a and b). She

had no oral thrush or lymphadenopathy. Chest and cardiovascular examination was unremarkable. Abdominal examination was also unremarkable apart from mild hepatomegaly.

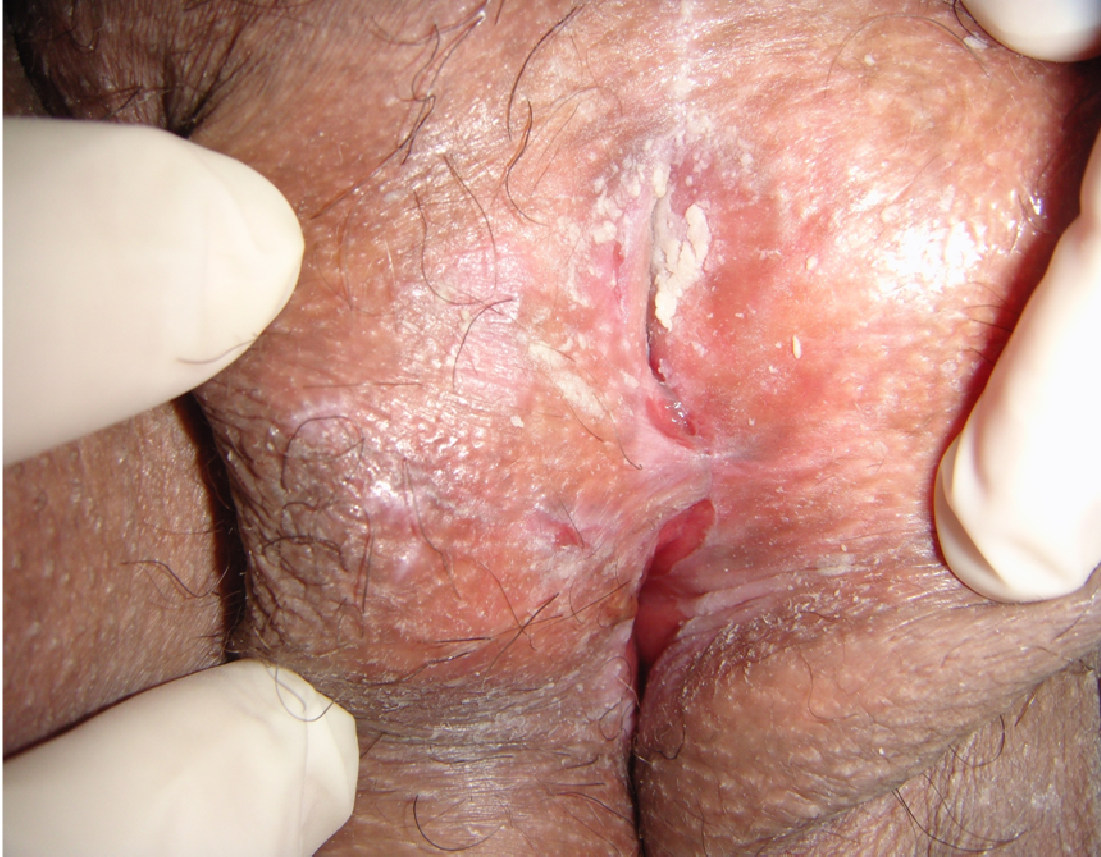

Figure 2. Partial fusion of the labia majora and minora.

Genital exam showed off-white to greyish plaques with partial fusion of labia majora and minora. Vaginal inspection revealed intense erythema and stenosis with friable mucosa that was easily ulcerating (Figures 2 and 3a and b).

Thus, the diagnosis of erosive lichen planus vulvovaginal syndrome was established. The patient was screened for other autoimmune diseases and all were negative. Serologic marker of HIV, HCV, and HBV were also non reactive. Abdominal ultrasound was normal with no evidence of perinephric collection. She underwent Cystoscopy which showed whitish plaques within the mucosa that was biopsied, whereas the histopathology examination revealed only inflammatory cells.

Once the diagnosis was made, she was reviewed by a dermatologist who recommended adding Tacrolimus vaginal suppositories, but she could not tolerate it. She was also seen by a gynaecologist who planned to go for adhesion release after controlling her active disease. She was started on intravenous methylprednisolone (80 mg) once daily along with Betamethasone vaginal cream and hydrocortisone vaginal enema.

After 10 days of therapy, the hematuria stopped completely. But 7 days later, she developed steroid induced psychosis, thus, the systemic steroids were held

and she continued on the local steroids, and Azathioprine (100 mg PO OD) was started. She was assessed by a psychiatrist who diagnosed her to have depression and started her on antidepressants. Unfortunately, few days later, she had a relapse of her symptoms and hematuria. So, IV systemic steroids were restarted again then shifted to oral prednisolone after 10 days of IV therapy.

Repeated vaginal examination showed marked improvement with partial release of the adhesions, less ulceration and markedly less pain. Therefore, her local steroids were changed to ultra potent steroid (Clobetasol) and Azathioprin dose was increased to 200 mg PO OD. Oral steroids were tapered to 10 mg OD. Later, she developed an episode of fresh rectal bleeding. Rectal examination showed only haemorrhoids. Colonoscopy was arranged to rule out the rectal involvement with the same disease but it was normal apart from congested internal haemorrhoids that was managed conservatively.

She was discharged on the 10th of May free of symptoms on Prednisolone (10 mg OD) and Azathioprine (200 mg OD).

She was followed in the clinic on weekly basis; her vaginal symptoms improved, and hematuria or abdominal pain was no longer observed. Even her depression improved also; she stopped all her anti-depressants as

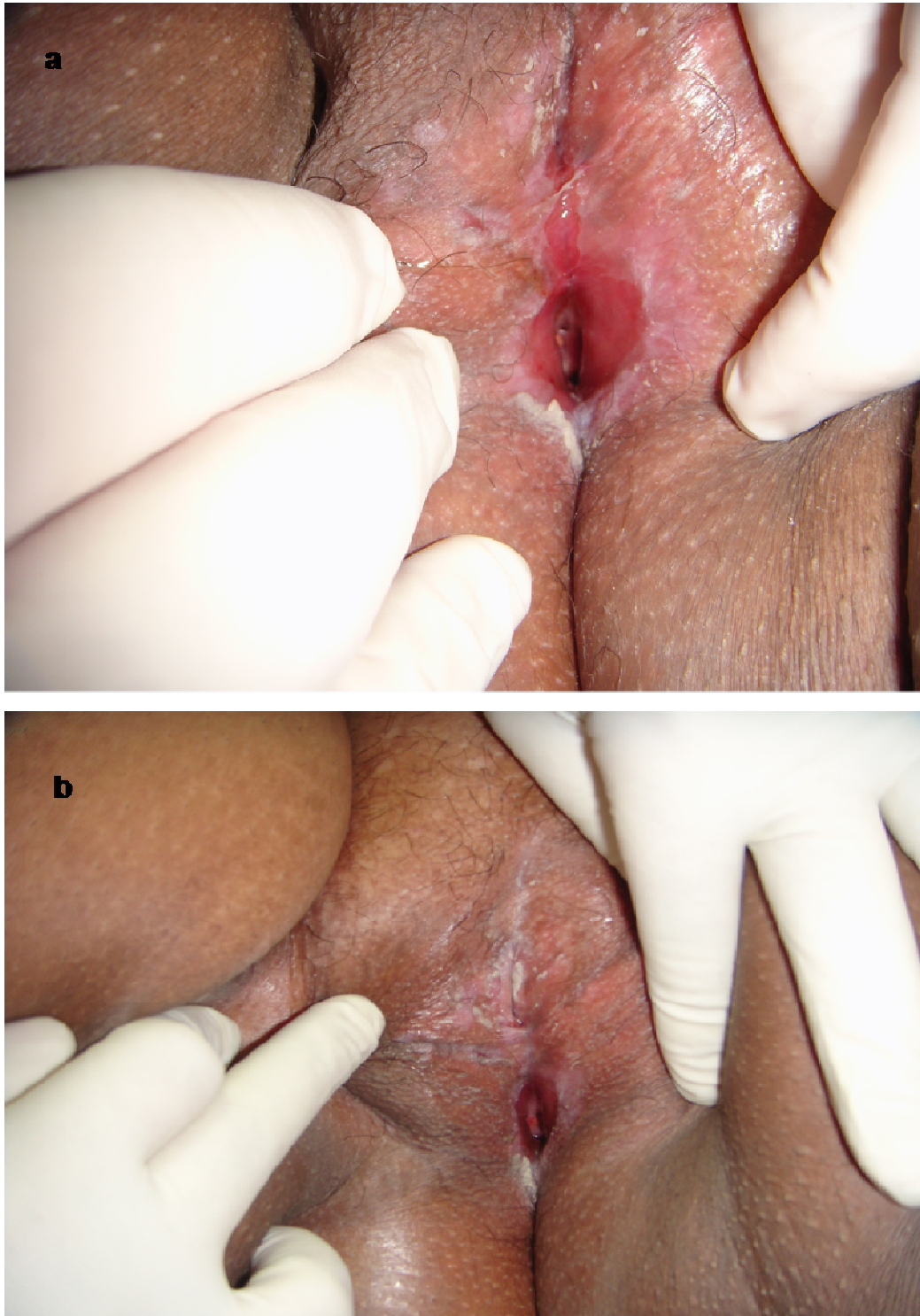


Figure 3. Intensely inflamed vaginal mucosa with off white to grayish plaques.

well as local steroids. Her last clinic visit was five months after discharge from the hospital, but unfortunately she was lost for follow up since then as she had travelled outside the country to pursue her studies.

DISCUSSION

This case addresses the importance and usefulness of thorough physical examination and correlation of findings

to the patient history. Lichen planus is a relatively uncommon disease of unknown etiology. The frequency of LP varies on the basis of the population studied, with a particularly high rate of disease noted on the Indian subcontinent (Julia et al., 2009). LP most commonly affects middle-aged people, although childhood-onset LP has also been well described. Vulvovaginal and penile lichen planus have been believed to be uncommon disease. However, with the improved awareness of the appearance and existence of LP, this condition is being diagnosed more frequently. About 1% of the population has oral lichen planus (Moyal-Barracco and Edwards, 2004). Of women with oral lichen planus, approximately 20-25% have vulvovaginal involvement (Eisen, 2003, 1999).

This condition can be associated with a spectrum of autoimmune diseases like ulcerative colitis (Boyd and Nelder, 1991), alopecia areata, vitiligo, dermatomyositis (Bhattacharya et al., 2000) and myasthenia gravis. Thymoma has been reported in association with LP (Gibson and Muller, 1987). In a study of 172 patients with LP, two had thymoma. Resection of thymoma tends not to improve LP (Hayashi et al., 2008). Good syndrome, an adult immunodeficiency state requiring long term immunoglobulin replacement, has been reported in oral LP (Lolis and Levitt, 2006; Seneschal et al., 2008) and vulvovaginal gingival LP (Moutasim et al., 2008). LP has also been linked with Laugier-Hunziker syndrome (Aytekin and Alp, 2004), primary biliary cirrhosis (Graham-Brown et al., 1982), primary sclerosing cholangitis (Tong and Ferguson, 2002), and diabetes mellitus (Boyd and Nelder, 1991).

A bidirectional relationship appears to exist between LP and psychosocial stress (Manolache et al., 2008). As such, a high prevalence of HCV has been observed in erosive mucosal LP, suggesting causal relationship (Sanchez-Perez et al., 1996; Nagao et al., 1996; Gimenez-García and Pérez-Castrillón, 2003). Some experts recommend routine hepatitis screening, particularly in patients with persistent or oral disease, or in patients where the disease is located in areas with high rates of hepatitis C infection.

Vulvovaginal gingival syndrome is a subtype of LP characterized by oral and genital involvement, and tends to heal with scarring. This entity has been found to be associated with class II human leukocyte antigen (HLA) allele DQB1*0201 (Setterfield et al., 2006). Treatment of vulvovaginal gingival syndrome is very difficult, as the disease runs an extremely chronic course in most of the patients. Nonspecific measures such as cool compressors and lidocaine jelly (2%) can decrease the burning and pain during maturation.

Women with vaginal LP should be instructed to use vaginal dilators daily to minimize the risk of vaginal scarring and adhesions. Topical potent (fluocinonide, 0.05%) or ultra-potent (colbetasol propionate, 0.05%) corticosteroids are the first line therapy for LP. Patients

should be examined frequently because they are prone to develop infections particularly fungal and herpes.

Topical cyclosporine has been shown to benefit oral LP but its efficacy in genital LP has not been fully demonstrated except in one study that showed significant decrease in eroded areas in 12 patients after 3 months of therapy (Pelisse et al., 1991).

Recently, small open label trials and case reports have shown that tacrolimus, another topical immunomodulator, could be useful for erosive oral and vaginal LP, but its use is limited by local irritation (Olivier et al., 2002; Morrison et al., 2002; Kirtschig et al., 2002). When it is inserted into the vagina by an applicator, tacrolimus can be absorbed producing serum level similar to those achieved by oral administration, so monitoring of the level is indicated in such patients. However, neither tacrolimus ointment applied using fingers nor tacrolimus suppositories produce significant serum level.

Systemic therapy of genital LP should be considered only after failure of topical treatment. These drugs include oral steroids and hydroxychloroquine. Anti-metabolites like azathioprine, methotrexate and cyclophosphamide have been reported to be effective in patients with erosive disease.

Surgical lysis of the adhesions is contraindicated in the setting of active disease as it may lead to more scarring. It should be performed by an experienced surgeon after achieving remission. Vaginal molds should be inserted immediately into the vagina after surgery to prevent recurrence of adhesions as well as the regular use of topical steroids. In men, circumcision is a simple measure which may significantly change the course of LP.

In conclusion, genital lichen planus in its erosive form is a painful, scarring and subsequently sexually disabling condition. It can be missed easily if the physician has little or no experience with such condition. Occasionally, lichen planus remits, sometimes after significant scarring. It is usually an intermittent life-long disease that can be much improved but not always completely controlled with medication (Moyal-Barracco and Edwards, 2004).

Management of such patients should include medications, supportive care, patient education and emotional support to provide significant improvement in the quality of life.

REFERENCES

- Aytekin S, Alp S (2004). Laugier–Hunziker syndrome associated with actinic lichen planus. *J. Eur. Acad. Dermatol. Venereol.*, 18: 221-242.
- Bhattacharya A, Kaur I, Kumar B (2000). Lichen planus: A clinical and epidemiological study. *J. Dermatol.*, 27: 576-582.
- Boyd AS, Nelder KH (1991). Lichen planus. *J. Am. Acad. Dermatol.*, 25: 593.
- Eisen D (1999). The evaluation of cutaneous, genital, scalp, nail, esophageal, and ocular involvement in

- patients with oral lichen planus. *Oral Surg. Oral Med. Oral Pathol. Oral Radiol. Endod.*, 88(4): 431-436.
- Eisen D (2003). Paper presented at the annual meeting of the American academy of Dermatology, Sanfrancisco, CA, March 2003.
- Gibson LE, Muller SA (1987). Dermatologic disorders inpatients with thymoma. *Acta Derm. Venereol.*, 67: 351-356.
- Gimenez-García R, Pérez-Castrillón J (2003). Lichen planus and hepatitis C virus infection. *J. Eur. Acad. Dermatol. Venereol.*, 17: 291-295. doi: 10.1046/j.1468-3083.2003.00631.x
- Graham-Brown RA, Sarkany I, Sherlock S (1982). Lichen planus and primary biliary cirrhosis. *Br. J. Dermatol.*, 106: 699-703
- Hayashi A, Shiono H, Okumura M. Thymoma accompanied by lichen planus. *Interact. Cardiovasc. Thorac. Surg.*, 7: 347-348.
- Julia SL, Megha M, Lawrence EG (2009). Lichen planus review. *Int. J. Dermatol.*, 48: 682.
- Kirtschig G, Van Der Meulen AJ, Ion Lipan JW, Stoof TJ (2002). Successful treatment of erosive vulvovaginal lichen planus with topical tacrolimus. *Br. J. Dermatol.*, 147: 625-626.
- Lolis M, Levitt J (2006). A case of oral lichen planus with Goods syndrome. *Dermatol. Online J.*, 12: 28
- Manolache L, Seceleanu-Petrescu D, Benea V (2008). Lichen planus patients and stressful events. *J. Eur. Acad. Dermatol. Venereol.*, 22: 437-441.
- Morrison L, Kratochvil FJ, III, Gorman A (2002). An open trial of topical tacrolimus for erosive oral lichen planus. *J. Am. Acad. Dermatol.*, 47: 617-620.
- Moutasim KA, Poate TW, Setterfield JF (2008). A case of vulvovaginal gingival lichen planus in association with Good's syndrome. *Oral Surg. Oral Med. Oral Pathol. Oral Radiol. Endod.*, 2008: e57-e60.
- Moyal-Barracco M, Edwards L (2004). Diagnosis and therapy of anogenital lichen planus. *Dermatologic Ther.*, 17: 38-46. doi: 10.1111/j.1396-0296.2004.04005.x.
- Nagao Y, Sata M, Ide T, Suzuki H, Tanikawa K, Itoh K, Kameyama T (1996). Development and exacerbation of oral lichen planus during and after interferon therapy for hepatitis C. *Eur. J. Clin. Investig.*, 26: 171-174.
- Olivier V, Lacour JP, Mousnier A, Garraffo R, Monteil RA, Ortonne JP (2002). Treatment of chronic erosive oral lichen planus with low concentrations of topical tacrolimus: an open prospective study. *Arch Dermatol* 2002; 138: 1335-1338
- Pelisse M, Boisnic S, Moyal-Barracco M, Szpiglas H, Reigneau O, Frances C (1991). Treatment of vulvovaginal erosive lichen planus with topical Cyclosporin A (CsA). Paper presented at the 11th World Congress of the International Society for the Study of Vulvar Disease, Oxford, UK, September 25, 1991.
- Sanchez-Perez J, De-Castro M, Buezo GF, Fernandez-Herrera J, Borque MJ, Garcia-Diez A (1996). Lichen planus and hepatitis C: prevalence and clinical presentation of patients with lichen planus and hepatitis C virus. *Br. J. Dermatol.*, 134: 715 ± 719.
- Seneschal J, Orlandini V, Duffau P (2008). Oral erosive lichen planus and Good's syndrome: just a coincidence or a direct link between the two diseases? *J. Eur. Acad. Dermatol. Venereol.*, 22: 506-507
- Setterfield JF, Neill S, Shirlaw PJ (2006). The vulvovaginal gingival syndrome: a severe subgroup of lichen planus with characteristic clinical features and a novel association with the class II HLA DQB1*0201 allele. *J Am Acad Dermatol* 2006; 55: 98-113.
- Tong DC, Ferguson MM (2002). Concurrent oral lichen planus and primary sclerosing cholangitis. *Br. J. Dermatol.*, 147: 356-358.